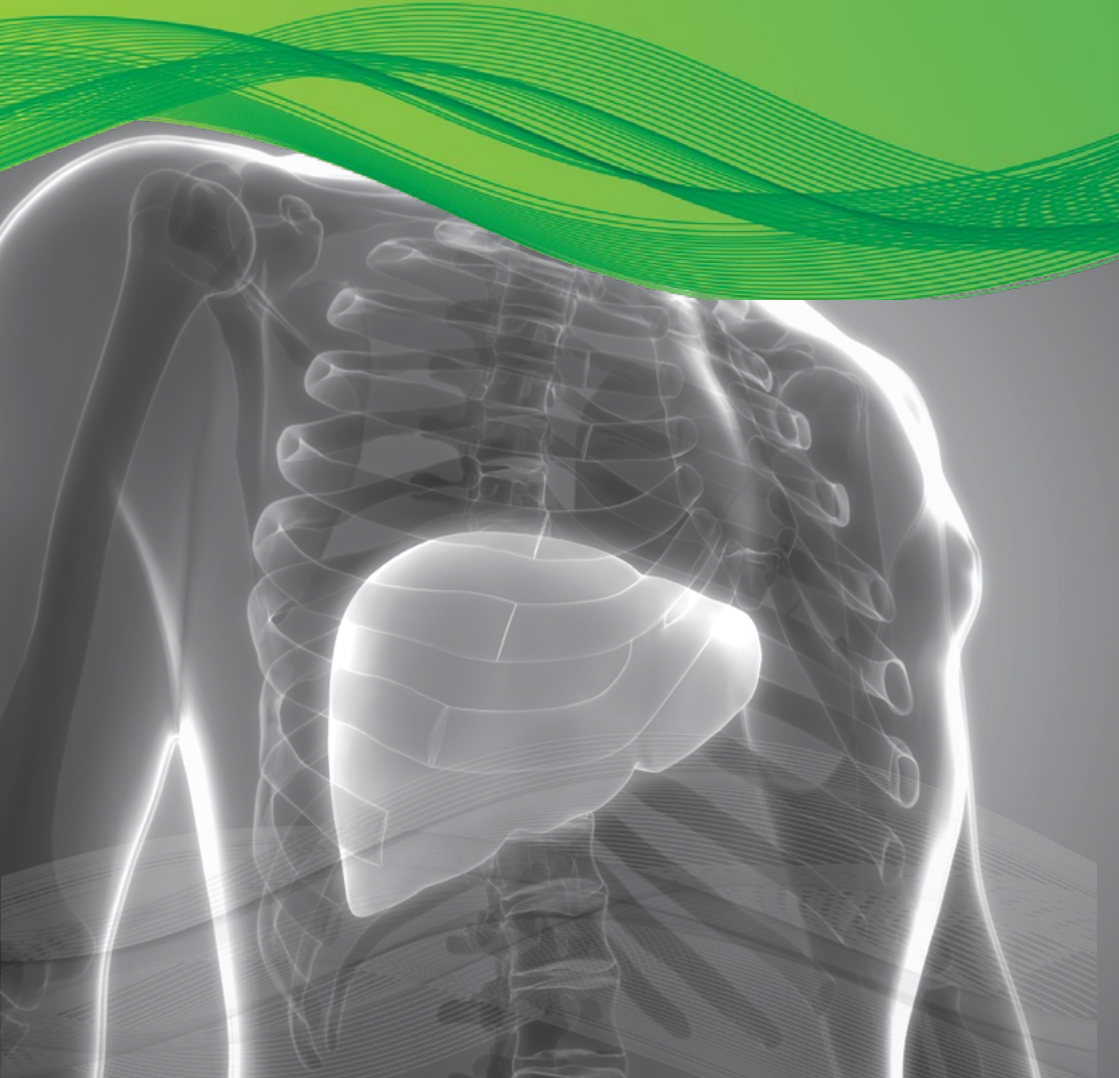

Diagnostic
Green

IC-Green® (indocyanine green for injection)

Liver Focus



www.diagnosticgreen.com

Diagnostic Green is the leading provider of trusted high quality fluorescence products, for physicians worldwide.

With primary liver cancer and colorectal liver metastases amongst the most common leading causes of cancer-related deaths worldwide, surgery represents one of the main treatments to obtain the best results in overall and disease free survival.¹ IC-Green® (indocyanine green for injection) in recent years has experienced increased interest in use for its clearance parameters as a dynamic assessment of liver function both in medical and surgical settings.² ICG is used routinely to evaluate hepatic function and liver blood flow.³ It is one of the most common and easy-to-use tests for the perioperative dynamic assessment of liver function in cases of major liver surgery (resective surgery and liver transplantation) and in the intensive care unit.

USE OF ICG, IN LIVER FUNCTION DIAGNOSTICS INCLUDE:

- ⊙ Measurement of excretory function of the liver
- ⊙ Measurement of liver blood flow

While numerous clinical parameters are used to assess a patient's liver function, the ICG test is the gold standard and is the only established test for estimating true global liver function.⁴ Assessment of dynamic liver function is crucial in the pre-operative preparation of those who require extensive liver resections, liver transplants and also to monitor liver function in a post-operative setting.

The ICG clearance or the elimination test is the most widely used quantitative liver function test. Following administration of ICG I.V., serial blood samples are collected at 5, 15, 20, 25 & 30 mins. The ICG blood levels fall exponentially for about 20mins, by which time approximately 97% of the ICG is excreted. After processing the samples, the ICG-R15 (at 15 mins) is determined as a percentage.

QUANTITATIVE MEASUREMENT

- ⊙ ICG Retention 15mins (ICG-R15) (Normal <10%)
- ⊙ Pulse Dye Densitometry – LiMON device
- ⊙ ICG Plasma Disappearance Rate (ICG-PDR) (Normal > 18%/min)⁵

ICG CLEARANCE TESTS

- ⊙ Pre and post Liver Resections
- ⊙ Pre and post Liver Transplant Surgery
- ⊙ Acute Liver Failure (ICU setting)

LAPAROSCOPIC LIVER RESECTION (LLR)

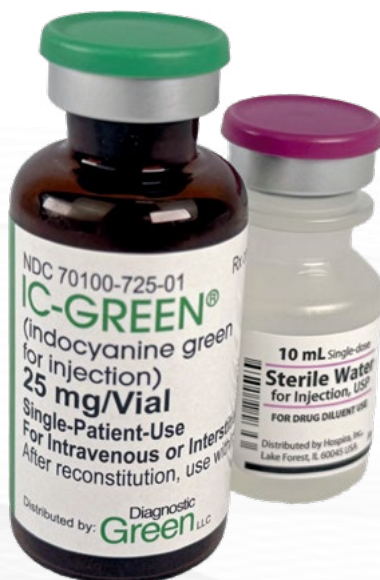Since the first Laparoscopic Liver Resection (LLR) was first preformed in 1991, the number of LLR's has increased with the advancements of surgical techniques and technology. LLR for Hepatocellular Carcinoma (HCC) is now considered standard treatment for minor liver resection.⁶ Laparoscopic surgery and robotic surgery have solved the issue of large incisional wounds, a major drawback of open liver surgery.⁷ While there are significant advantages associated with a laparoscopic technique (less bleeding, shorter length of hospital stay, decreased morbidity and possibly lower mortality), adoption by a surgeon does mean that the ability to touch and palpate the organ is eliminated. By using ICG in these circumstances, increasing the visualization of the anatomy adds to procedure success.

ICG USE IN LIVER RESECTIONS – FIRST LINE TREATMENT FOR HEPATOCELLULAR CARCINOMA (HCC)

Over the last few decades, imaging technologies in hepatobiliary (HPB) surgery have become indispensable tools for liver surgeons. The ICG fluorescence imaging (FI) technique helps to guide the hepatic surgical procedures and provides the surgeon with real-time visualization of the fluorescent structures of interest that would be invisible under conventional white light. The extrahepatic bile duct anatomy and liver tumors can be emphasized, and hepatic segments highlighted, based on the fluorescence property of ICG and its biliary excretion.

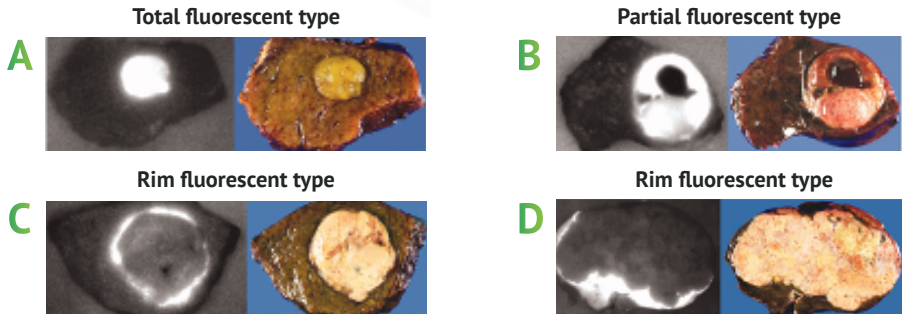
COLORECTAL LIVER METASTASES AND LIVER TRANSPLANT USE OF ICG

Additionally, a recent retrospective multi-center analysis of 174 patients showed that the use of ICG identifies significantly more and smaller tumors during colorectal liver metastases (CRLM) resection.⁸ For liver transplantation, use of ICG has shown to be the best curative treatment of chronic liver diseases/HCC/acute liver failure. Increasing the use of marginal grafts can lead to increased incidence of primary non-function (PNF) after transplantation with few early predictors available for PNF. By undertaking quantitative assessment of intra-operative ICG fluorescence on the graft, a 2020 study has shown that it was feasible to predict graft survival at three months with good sensitivity and specificity.⁹



ICG AND TUMOR VISUALIZATION .

For intra-operative visualization of liver tumour, ICG is administered I.V. two weeks prior to surgery.¹⁰

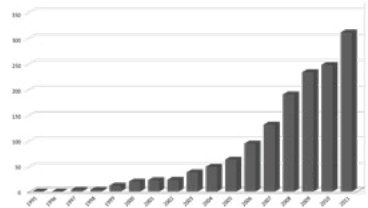


- A** Total fluorescent type – well differentiated hepatocellular carcinoma (HCC), 7mm in diameter
- B** Partial fluorescent type – moderately differentiated HCC with well differentiated components and hemorrhagic necrosis at upper half of the tumor, 36mm in diameter
- C** Rim fluorescent type – poorly differentiated HCC, 30mm in diameter
- D** Rim fluorescent type – metastasis in colon carcinoma, 130mm in diameter

Italy snapshot of LLR surgeries in practice ¹¹

- ⊙ LLR represents 10.3% of all Liver Resections (1677 cases)
- ⊙ Malignant lesions 72.5% (1085 cases)
 - ⊙ 56% - Hepatocellular Carcinoma (HCC)
 - ⊙ 28% - Colorectal Liver Metastases (CRLM)
- ⊙ Overall mortality 0.2%
- ⊙ Mean length of stay → five days

GROWTH IN MINIMALLY INVASIVE LIVER SURGERIES BY YEAR IN ITALY (FROM 50 IN 2005 TO OVER 300 IN 2011)



SUMMARY OF ICG, IN LIVER SETTING

- ⊙ Liver Function Assessment – Pre & Post Op
- ⊙ Intra-operative identification of anatomic liver segments
- ⊙ After reconstruction of hepatic vessels – assessment of liver inflow and outflow of blood
- ⊙ Visualization of Liver Tumors (HCC & CRLM)*
- ⊙ Useful for real-time detection of bile leaks during liver resection
- ⊙ Supports living donor liver transplantation

*Note - Tumor Visualization and ICG is currently an investigational use.

ICG USE - BENEFITS TO THE SURGEON

- ⊙ Real time visualization of anatomical structures
- ⊙ Simple method to evaluate hepatic function
- ⊙ Allows for safe use of marginal liver grafts
- ⊙ Easy to use test for dynamic assessment of liver blood flow
- ⊙ Helps identify more and smaller colorectal tumours
- ⊙ Quantitative liver function test

REFERENCES:

- ¹Torre LA, Bray F, Siegel RL, Ferlay J, Lortet-Tieulent J, Jemal A. Global cancer statistics, 2012. *CA Cancer J Clin*. 2015;65:87–108. [PubMed] [Google Scholar]
- ²Indocyanine green kinetics to assess liver function: Ready for a clinical dynamic assessment in major liver surgery? Andrea De Gasperi, Ernestina Mazza, and Manlio Prosperi, *World J Hepatol*. 2016 Mar 8; 8(7): 355–367. Published online 2016 Mar 8. doi: 10.4254/wjh.v8.i7.355
- ³Fluorescence guided surgery in liver tumours: applications and advantages. Rossi Giorgio, Tarasconi Antonio, Baiocchi Gianluca, Luigi deAngelis Gian, Gaiani Federica, Di Mario Francesco, Catena Fausto, and Dalla Valle Raffaele *Acta Biomed*. 2018; 89(Suppl 9): 135–140. doi: 10.23750/abm.v89i9-S.7974
- ⁴Geisel D, Lüdemann L, Hamm B, Denecke T. Imaging-Based Liver Function Tests--Past, Present and Future. *Rofo*. 2015;187(10):863–871. doi:10.1055/s-0035-1553306
- ⁵APA Sakka, Samir G. Assessing liver function, *Current Opinion in Critical Care*: April 2007 - Volume 13 - Issue 2 - p 207-214
- ⁶Kaneko J, Kokudo T, Inagaki Y, Hasegawa K. Innovative treatment for hepatocellular carcinoma (HCC). *Transl Gastroenterol Hepatol*. 2018;3:78. Published 2018 Oct 22. doi:10.21037/tgh.2018.10.04.
- ⁷The history of liver surgery: Achievements over the past 50 years. Norihiro Kokudo, Nobuyuki Takemura, Kyoji Ito, Fuminori Mihara. First published: 26 February 2020 <https://doi.org/10.1002/ags3.12322>
- ⁸Handgraaf HJM, Boogerd LSF, Höppener DJ, et al. Long-term follow-up after near-infrared fluorescence-guided resection of colorectal liver metastases: A retrospective multicenter analysis. *Eur J Surg Oncol*. 2017;43(8):1463–1471. doi:10.1016/j.ejso.2017.04.016
- ⁹Dousse D, Vibert E, Nicolas Q, et al. Indocyanine green fluorescence imaging to predict graft survival after orthotopic liver transplantation: a pilot study [published online ahead of print, 2020 May 13]. *Liver Transpl*. 2020;10.1002/lt.25796. doi:10.1002/lt.25796
- ¹⁰Shizawa T, Fukushima N, Shibahara J, et al. Real-time identification of liver cancers by using indocyanine green fluorescent imaging. *Cancer*. 2009;115(11):2491–2504. doi:10.1002/cncr.24291
- ¹¹Aldrighetti L, Belli G, Boni L, et al. Italian experience in minimally invasive liver surgery: a national survey. *Updates Surg*. 2015;67(2):129–140

IC-GREEN® (INDOCYANINE GREEN FOR INJECTION), FOR INTRAVENOUS OR INTERSTITIAL USE - PRESCRIBING INFORMATION

HIGHLIGHTS OF PRESCRIBING INFORMATION

These highlights do not include all the information needed to use IC-Green® (indocyanine green for injection) for intravenous or interstitial use safely and effectively. See full prescribing information for IC-Green® (indocyanine green for injection), for intravenous or interstitial use.

INDICATIONS AND USAGE

IC-Green® (indocyanine green for injection) is a tricarbocyanine dye, is indicated for:

- Fluorescence imaging of vessels (micro- and macro-vasculature), blood flow and tissue perfusion before, during and after vascular, gastrointestinal, organ transplant, plastic, micro- and reconstructive surgeries, including general minimally invasive surgical procedures, in adults and pediatric patients aged 1 month and older
- Fluorescence imaging of extrahepatic biliary ducts in adults and pediatric patients aged 12 years and older
- Fluorescence imaging of lymph nodes and lymphatic vessels during lymphatic mapping in adults with cervical and uterine cancer
- Ophthalmic angiography in adults and pediatric patients

DOSAGE AND ADMINISTRATION

Indicator-Dilution Studies.

Under sterile conditions, the IC-Green® (indocyanine green for injection) powder

should be dissolved with the Sterile Water for Injection, USP provided and the solution used within 6 hours after it is prepared. The usual doses of IC-Green® (indocyanine green for injection) for dilution curves are: Adults 5.0 mg, Children - 2.5 mg, and Infants - 1.25 mg.

Hepatic Function Studies.

Under sterile conditions, the IC-Green® (indocyanine green for injection) powder should be dissolved with the Sterile Water for Injection, USP provided. The patient should be weighed and the dosage calculated on the basis of 0.5 mg/kg of body weight. Exactly 5 mL of Sterile Water for Injection, USP should be added to the 25 mg vial giving 5 mg of dye per mL of solution.

Ophthalmic Angiography Studies.

Dosages up to 40 mg IC-Green® (indocyanine green for injection) dye in 2 mL of Sterile Water for Injection, USP should be administered. A 5 mL bolus of normal saline should immediately follow the injection of the dye.

DOSAGE FORMS AND STRENGTHS

IC-Green® (indocyanine green for injection) Injection is a sterile, lyophilized green powder containing 25 mg of indocyanine green with no more than 5% sodium iodide.

CONTRAINDICATIONS

IC-Green® (indocyanine green for injection) Injection contains sodium iodide and should be used with caution in patients who have a history of allergy to iodides because of the risk of anaphylaxis.

WARNINGS AND PRECAUTIONS

- Hypersensitivity reactions including anaphylaxis and urticaria have occurred. Always have cardiopulmonary resuscitation personnel and equipment readily available to monitor patients.
- IC-Green® (indocyanine green for injection) is unstable in aqueous solution and must be used within 6 hours
- Radioactive iodine uptake studies should not be performed for at least a week following the use of IC-Green® (indocyanine green for injection).

ADVERSE REACTIONS

Most common adverse reactions are anaphylactic or urticarial reactions. These have been reported in patients with and without a history of allergy to iodides.

To report SUSPECTED ADVERSE REACTIONS, contact Diagnostic Green LLC at 1-844- 424-3784 (1-844-ICG-DRUG) or e-mail: drugsafety@diagnosticgreen.com; or FDA at 1-800-FDA-1088 or www.fda.gov/medwatch.

DRUG INTERACTIONS

Products containing sodium bisulfite reduce the absorption peak of IC-Green® (indocyanine green for injection) in blood.

For full prescribing information go to www.diagnosticgreen.com

Diagnostic
Green

© 2025 Diagnostic Green
info@diagnosticgreen.com
www.diagnosticgreen.com

Diagnostic Green Ltd
IDA Business Park Garrycastle
Athlone, Co. Westmeath
N37 F786, Ireland

Diagnostic Green LLC
38955 Hills Tech Drive
Farmington Hills
MI 48331, United States