



# CASE REPORT

Dr. Cyrus Jahansouz, Dr. Hayim Gilshtein,  
Dr. Steven D. Wexner, Cleveland Clinic Florida,

## **Evaluation of Anastomotic Perfusion following Laparoscopic Anterior Resection with Coloanal Anastomosis**

## SUMMARY

A cornerstone of colorectal surgery is the bowel anastomosis. Anastomotic leak is a devastating complication to the patient that can result in infection, sepsis, and even death.<sup>1</sup> Healing of the anastomosis depends on both the patient's general health condition as well as technical factors related to surgery, namely the creation of a well perfused and tension free anastomosis.<sup>2,3</sup>

The evaluation of anastomotic perfusion at the time of surgery remains a significant challenge, even to the most experienced of colorectal surgeons. Ensuring adequate blood flow at the anastomosis has the potential to reduce anastomotic leaks and improve patient outcomes following colorectal surgery. Real-time visualization of tissue perfusion using the Indocyanine Green (ICG) pharmaceutical enables real-time assessment of anastomotic tissue perfusion allowing for a rapid determination of adequacy of the bowel anastomosis.<sup>4-6</sup>

## CASE

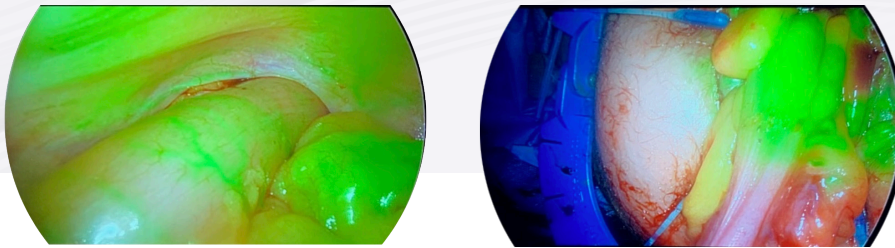
**The following case study discusses a patient who underwent laparoscopic anterior resection with coloanal anastomosis for rectal cancer.**

The patient is a 77 year old female who presented after a rectal mass was discovered during colonoscopy. Further imaging and biopsy results were consistent with the diagnosis of a Stage 2 (T3, N0, M0) rectal cancer, the distal edge of which was situated approximately 7 cm from the anal verge. After discussion at National Accreditation for Rectal Cancer multidisciplinary tumor board, a laparoscopic anterior resection with coloanal anastomosis was offered to the patient.

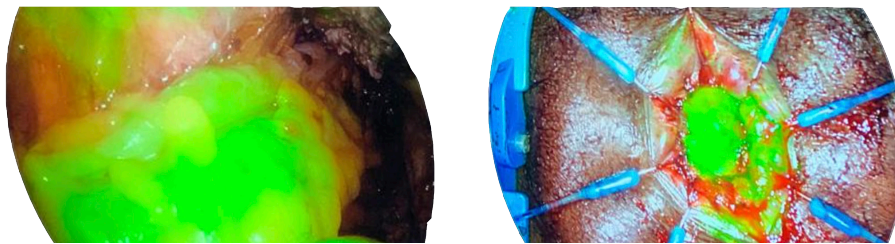
## PROCEDURE

The procedure began laparoscopically with mobilization of the descending and sigmoid colon and splenic flexure, followed by high ligations of the inferior mesenteric artery and vein. The mesentery was intracorporeally divided to the distal descending colon and a total mesorectal excision was undertaken. A Lone Star retractor® (Cooper Surgical, Trumbull, CT) was placed and a circumferential full thickness incision was made 1 cm above the dentate line. Once dissection was completed, the specimen containing the tumor was carefully delivered through a wound protector placed through the enlarged umbilical port site. After resection of the rectosigmoid, a 5 cm x 5 cm colonic J-pouch was fashioned and delivered to the perineum; 3.5 mL of Indocyanine Green for Injection,

USP (ICG) followed by 10 mL of saline solution was administered. Fluorescence angiography confirmed excellent serosal perfusion of the colonic J pouch (Figure A). A hand-sewn coloanal anastomosis was then fashioned, and an additional 3.5 mL of ICG was administered confirming excellent mucosal perfusion of the anastomosis (Figure B). In addition, a reverse leak test was undertaken.<sup>7</sup>



**Figure A.**  
*Colonic J-pouch delivered to perineum with ICG confirming excellent perfusion*



**Figure B.**  
*ICG readministered following completion of hand-sewn coloanal anastomosis confirmed excellent perfusion to anastomosis*

## CONCLUSION

The patient tolerated the surgery well, and was discharged without complications on post-operative day five.

Intraoperative implementation of ICG allowed for rapid easy evaluation of the colon both prior to and following the creation of the hand-sewn coloanal anastomosis. Its utility and convenience provided us with an additional tool to help us optimize patient outcomes. We routinely perform quadruple assessment of more proximal colorectal, coloanal, ileorectal, and ileoanal circular stapled anastomoses with tissue donut inspection, endoscopic visualization, air leak testing, and ICG perfusion assessment.<sup>8</sup>



## REFERENCES

1. Albert JC, Parvaiz A, Moran BJ. Predicting risk and diminishing the consequences of anastomotic dehiscence following rectal resection. *Colorectal Dis.* 2003 Sep;5(5):478-82.
2. Chadi SA, Fingerhut A, Berho M, et al. Emerging trends in the etiology, prevention, and treatment of gastrointestinal anastomotic Leakage. *J Gastrointest Surg.* 2016 Dec;20(12):2035-2051.
3. Vallance A, Wexner SD, Berho M, et al. A collaborative review of the current concepts and challenges of anastomotic leaks in colorectal surgery. *Colorectal Dis.* 2017 Jan;19(1):O1-O12.
4. Jafari J, Wexner SD, Martz JE, et al. Perfusion assessment in laparoscopic left-sided/anterior resection (PILLAR II): a multiinstitutional study. *J Am Coll Surg.* 2015 Jan;220(1):82-92.e1.
5. Mizrahi I, Abu-Gazala M, Rickles AS, et al. Indocyanine green fluorescence angiography during low anterior resection for low rectal cancer: results of a comparative cohort study. *Tech Coloproctol.* 2018 Jul;22(7):535-540.
6. Mizrahi I, de Lacy FB, Abu-Gazala M, et al. Transanal total mesorectal excision for rectal cancer with indocyanine green fluorescence angiography. *Tech Coloproctol.* 2018 Oct;22(10):785-791.
7. Emile SH, Wexner SD. The reverse leak Test for the assessment of low coloanal anastomosis: technical note. *Tech Coloproctol.* 2019 May;23(5):491-491.
8. Emile SH, Gilshtein H, Wexner SD. Quadruple assessment of colorectal anastomoses: A technique to reduce the incidence of anastomotic leakage. *Colorectal Dis* 2020 Jan;22(1):102-103.

Disclosures: CJ and HG have none; SDW accepts royalties and consulting fees from Storz (El Segundo, CA), Medtronic (Fridley, MN), and Intuitive (Sunnyvale, CA) and consulting fees from Takeda (Tokyo, Japan), Regentys (Miami Lakes, FL), and Stryker (Kalamazoo, MI).

Indocyanine Green for Injection, USP is available, in the USA via Diagnostic Green's distributor HUB Pharmaceuticals LLC. Call 1-844-ICG-VIAL (424-8425) or e-mail at [info@diagnosticgreen.com](mailto:info@diagnosticgreen.com) for more information. In a number of EMEA territories, the product is sold under the Verdye name. For territory specific information, go to [www.diagnosticgreen.com](http://www.diagnosticgreen.com).