



CASE REPORT

Sinikka Suominen, MD, PhD
Helsinki University Central Hospital,
Division of Plastic Surgery

Breast Flap Reconstruction

Skin Sparing Mastectomy (SSM) using Indocyanine Green (ICG) with the IC Flow™ Imaging System

SUMMARY

Today, breast reconstructive surgery performed simultaneously with the mastectomy procedure is considered best practice. As a result, the rates of skin sparing mastectomy (SSM) surgeries has increased in the last decade¹. The reasons for this are twofold. Firstly, surgeons can achieve superior aesthetic results compared to a conventional mastectomy or delayed reconstruction. Secondly, the patient undergoes both the therapeutic and reconstructive surgeries simultaneously, thus leading to improved patient satisfaction, psychological outcomes and cost effectiveness².

In order to preserve flap vascularity, the SSM requires a meticulous dissection technique. However, post-operative complications including flap necrosis and delayed wound healing remain common. Further, if volume replacement is carried out with implants, these post-operative complications may also lead to loss of the implant itself.

Real-time visualization of tissue perfusion using the Indocyanine Green (ICG) pharmaceutical with the IC-Flow™ Imaging System (Camera), allows the surgeon to check perfusion of the mastectomy skin flap, which helps the surgeon plan the final resection of the skin edges. Further, the ability to view tissue perfusion in real-time also permits the surgeon to check flap perfusion post anastomosis. According to Dr. Suominen, it is a highly sensitive diagnostic technique which helps prevent post-operative complications associated with breast reconstruction using flaps.

CASE

The following case study discusses a patient who underwent an immediate bilateral breast reconstruction with deep inferior epigastric perforator (DIEP) flaps.

The female patient is a 45yr old BRCA2 gene carrier with a family history of breast cancer (Figure 1). During follow-up, she presented with a suspicious lesion (<1 cm) in the left breast and a core needle biopsy confirmed ductal breast cancer. Due to her increased breast cancer risk, a bilateral nipple-sparing mastectomy and reconstruction with a bilateral DIEP flap was planned.

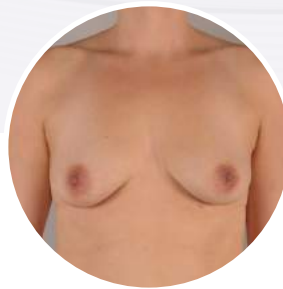


Figure 1.
Preoperative
clinical image.

PROCEDURE

First, the breast tissue was removed during a nipple and skin sparing mastectomy. Then, the breast mound was reconstructed during the same procedure using a DIEP flap.

In this procedure, the ICG fluorescence method using the IC-Flow™ Imaging System was performed for two purposes. Firstly, to assess the mastectomy skin flap edges and secondly to confirm the perfusion of the DIEP flap after the anastomosis.

After the nipple sparing mastectomy, DIEP flap inset and microvascular anastomosis was completed, the perfusion of the mastectomy skin flap was checked to determine the under-perfused areas using ICG. The flow of ICG dye to these areas was followed dynamically for 30-60 seconds, after which the

remaining dark areas (showing no detectable fluorescence) were resected, thus reducing the incidence of postoperative skin edge necrosis (Figure 2).

Further, the vascular perfusion of the DIEP flap (including skin epithelium) was also assessed. When the DIEP flap is buried under the breast skin, it is more challenging to evaluate its vascularity, which may have been compromised during the insertion. Also, at the end of the operation, blood pressure is often low making clinical evaluation difficult. The ICG perfusion method facilitates a simple, straightforward visual assessment of flap arterial flow, even before the clinical signs of compromised blood flow appear.

In this case, the skin island (the exposed DIEP flap) was not perfused, as demonstrated by the lack of ICG fluorescence, and the skin remained dark. A re-assessment at the anastomosis, confirmed an intraoperative arterial occlusion of the pedicle, which was successfully revised.

Next, the design of the skin island (exposed DIEP flap) was planned, followed by de-epithelization of the remaining DIEP flap (Figure 3).

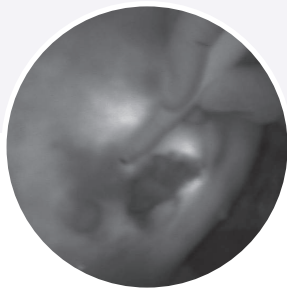


Figure 2.
Perfusion assessment
of the mastectomy
skin flap.

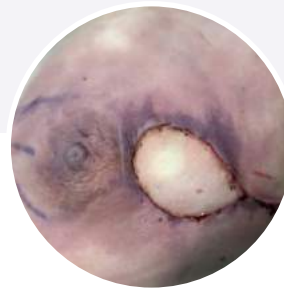

Figure 3.
Postoperative nipple
and skin sparing
mastectomy, with
skin island.

RESULTS

In this case, the IC-Flow™ Imaging System together with ICG dye assessment permitted the detection and removal of poorly perfused areas within the native mastectomy skin.

Additionally the camera detected under-perfusion of the DIEP flap skin island post insertion, thus allowing a revision to avoid post-operative flap necrosis.

The patient recovered successfully with no adverse events reported. Flaps were monitored clinically throughout the hospital stay, and no wound healing problems arose (Figure 4-5).

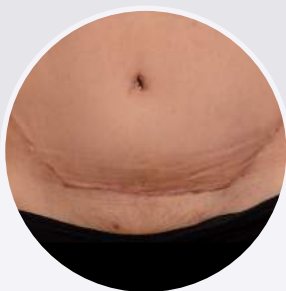

Figure 4.
*Post-operative DIEP flap
scar after 6 months.*

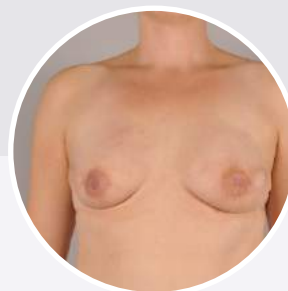

Figure 5.
*Post-operative breast
reconstruction after 6 months.*

CONCLUSION

ICG assessment has proven to be highly effective in the intraoperative evaluation of mastectomy skin flap perfusion. In the case of a microvascular DIEP flap reconstruction, its use provides the additional benefit of accurate evaluation of the flap perfusion. This allows for early intraoperative detection and salvage of potential vascular complications or thrombosis.

The IC-Flow™ Imaging System is a very simple and easy to use camera. Even inexperienced surgical staff can effectively use the camera system and make the necessary camera setting adjustments without too much instruction. Due to its compact size, it is easily transportable between different operating theatres and wards. Further, its small footprint does not impact on the already crowded operating theatre. Finally, the camera's ability to document clinical evidence with both videos or pictures is very useful and can be an essential tool to record and document the procedure.

REFERENCES

- ¹Agrawal A, Sibbering D, Courtney C. Skin sparing mastectomy and immediate breast reconstruction: a review. *Eur J Surg Oncol* 2013; 39: 320–328
- ²F. H. K. Jeon¹, J. Varghese^{1,2}, M. Griffin^{1,2}, P. E. Butler^{1,2}, D. Ghosh^{1,3} and A. Mosahebi^{1,2} Systematic review of methodologies used to assess mastectomy flap viability *BJS Open* 2018; 2: 175–184