



CASE REPORT

Use of Near-infrared Incisionless Fluorescent Cholangiography (NIFC) for Identification of the Anatomy in Biliary Surgery

Francisco A. Ferri, MD; Felice De Stefano, MD; Vicente J. Cogollo, MD; Alejandro Cracco, MD; Emanuele Lo Menzo, MD, PhD, FACS, FASMBS; Mayank Roy, MD, FACS; Fernando Dip, MD, FACS.

Department of General Surgery and the Bariatric and Metabolic Institute, Cleveland Clinic Florida.

Summary

Bile duct injuries during laparoscopic cholecystectomy remain a potentially devastating complications and are responsible for major morbidity and prolonged hospitalization¹. Visual misperception, anatomical variations in the extrahepatic biliary tree, combined with inflammatory changes and surgeon inexperience in recognizing the anatomy, are among the most common reasons for these injuries².

Near-infrared Incisionless Fluorescent Cholangiography (NIFC) has been shown to improve the visualization and identification of the biliary structures compared to traditional white light³⁻⁵.

The following case study discusses a 37 years old, morbidly obese woman (BMI 43 Kg/m²) with impaired fasting glucose and no significant surgical history who presented to the clinic with a 3-month history of right upper quadrant (RUQ) abdominal pain, especially after meals. The physical exam revealed tenderness in the RUQ with a negative Murphy sign and no evidence of peritonitis. An ultrasound showed a 3.8 cm gallstone (**Figure 1**) without gallbladder wall thickening and hepatic steatosis. Esophagogastroduodenoscopy did not reveal any pathologic findings. The patient was referred to the bariatric surgery clinic for evaluation in view of her elevated BMI and her comorbidity. After discussing surgical options, the patient elected to undergo a combined laparoscopic sleeve gastrectomy and cholecystectomy using NIFC.

Under general anesthesia, the abdominal cavity was accessed through an optical trocar in the supraumbilical position. After insertion of accessory trocars, a sleeve gastrectomy was performed in standard fashion. Next, 3mL of Indocyanine green for Injection, USP (ICG) were injected intravenously. The gallbladder was cranially retracted. The hepatoduodenal ligament was exposed. Using near-infrared imaging we identified the ICG perfusion times of the liver, common hepatic duct and gallbladder at 1, 12 and 22 minutes after the injection of the ICG, respectively (**Figures 2-4**).

The cystic duct and cystic artery entrance into the gallbladder were both clearly identified (**Figure 5**) and transected between clips. The very large and chronically inflamed gallbladder was excised from the liver bed in retrograde fashion and retrieved with the specimen through the umbilicus. All trocar sites were closed with sutures and injected with local anesthesia.

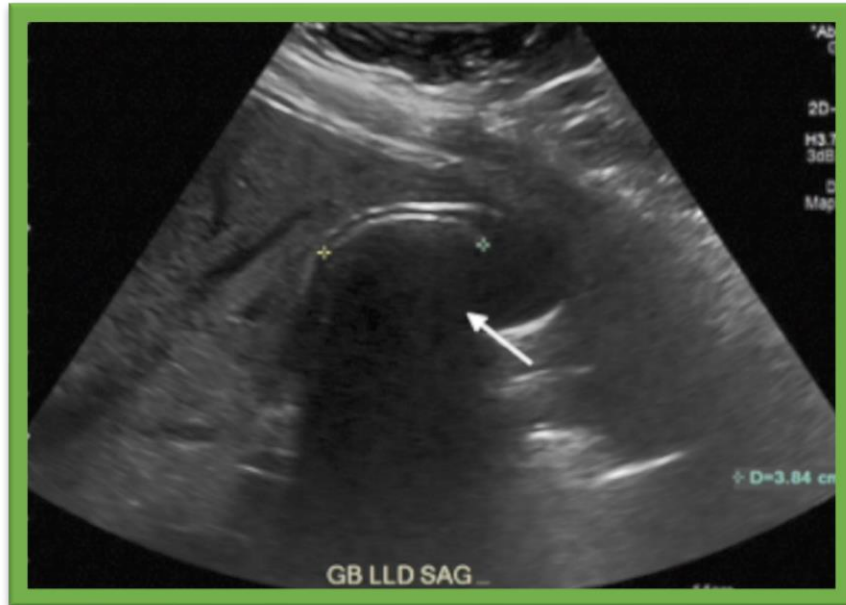

Figure 1. Right upper quadrant ultrasound revealing a 3.8cm gallstone

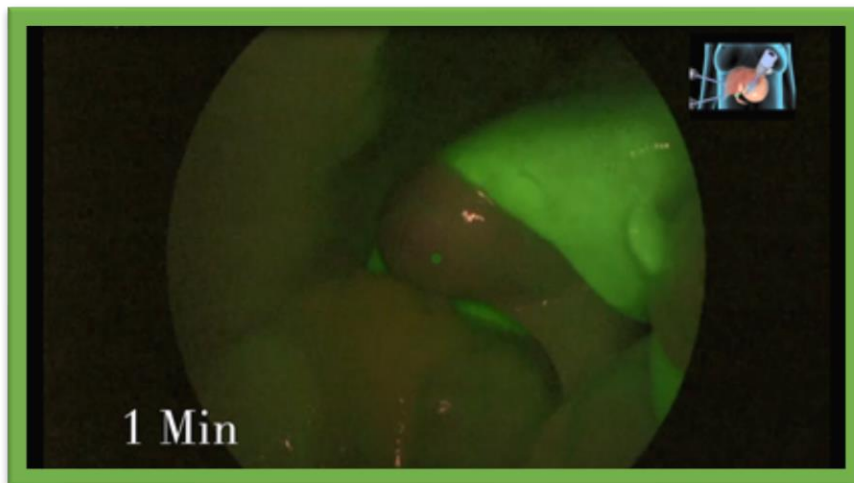


Figure 2: Liver visualization at 1 minute after the injection of ICG.

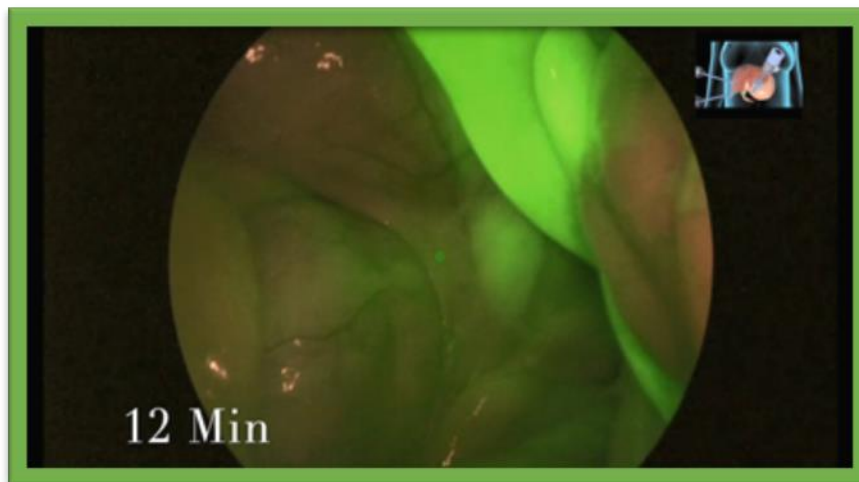


Figure 3: Common Hepatic Duct visualization at 12 minutes after the injection of ICG.

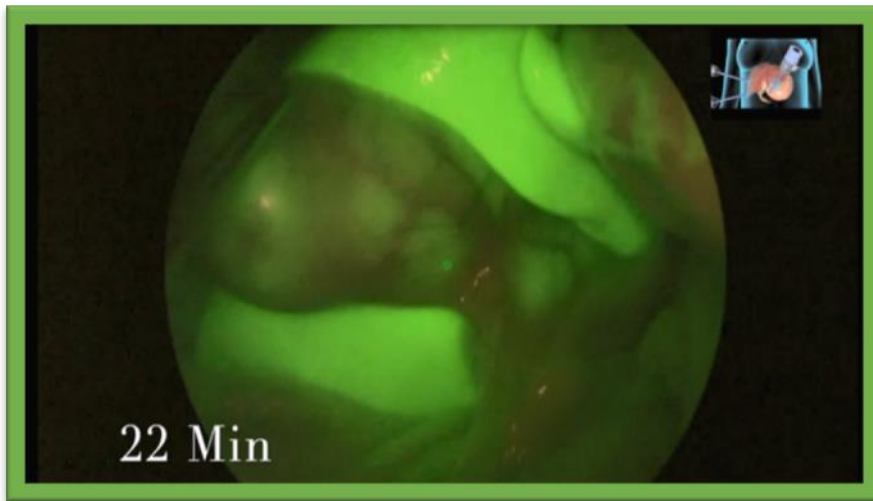
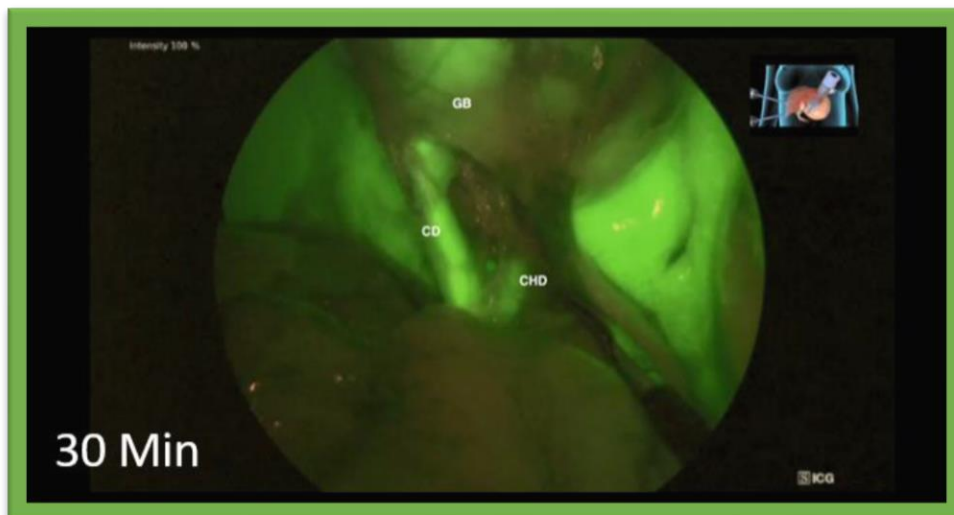


Figure 4: Gallbladder visualization at 22 minutes after the injection of ICG



**Figure 5: Clear identification of the biliary structures using NIFC.
GB: Gallbladder; CD: Cystic Duct; CHD: Common Hepatic Duct**

Conclusion

The patient tolerated the procedure without complications and was discharged home on postoperative day one. At one year follow-up, she has complete resolution of symptoms.

The ideal time of ICG injection during cholecystectomy remains controversial. However, even the intraoperative injection of ICG allows for a clear identification of the biliary structures in real time. This is a critical step in order to reduce the incidence of bile duct injuries.

References

1. Caratozzolo E, Massani M, Recordare A, et al. Usefulness of Both Operative Cholangiography and Conversion to Decrease Major Bile Duct Injuries During Laparoscopic Cholecystectomy. *J Hepatobiliary Pancreat Surg.* 2004;11(3):171-5. doi: 10.1007/s00534-003-0884-1.
2. Dip F, LoMenzo E, Sarotto L, et al. Randomized Trail of Near-infrared Incisionless Fluorescent Cholangiography. *Ann Surg.* 2019 Dec;270(6):992-999. doi: 10.1097/SLA.0000000000003178.
3. Dip F, Roy M, LoMenzo E, et al. Routine Use of Fluorescent Incisionless Cholangiography as a New Imaging Modality During Laparoscopic Cholecystectomy. *Surg Endosc.* 2015 Jun;29(6):1621-6. doi: 10.1007/s00464-014-3853-7.
4. Roy M, Dip F, Nguyen D, et al. Fluorescent Incisionless Cholangiography as a Teaching Tool for Identification of Calot's Triangle. *Surg Endosc.* 2017 Jun;31(6):2483-2490. doi: 10.1007/s00464-016-5250-x.
5. Pesce A, Piccolo G, La Greca G, et al. Utility of Fluorescent Cholangiography During Laparoscopic Cholecystectomy: A Systematic Review. *World J Gastroenterol.* 2015 Jul 7;21(25):7877-83. doi: 10.3748/wjg.v21.i25.7877.

Disclosures: FAF, VJC, AC, FD, MR have none; RJR, FD, and ELM accept consulting fees as advisory board members for Diagnostic Green (Farmington Hills, MI); RJR accepts consulting fees from Stryker (Kalamazoo).

Indocyanine Green for Injection, USP is available, in the USA via Diagnostic Green's distributor HUB Pharmaceuticals LLC. Call 1-844-ICG-VIAL (424-8425) or e-mail at info@diagnosticgreen.com for more information. In certain territories across the EMEA, the product is sold under the Verdye name. For territory specific information, go to www.diagnosticgreen.com.