



CASE REPORT

Indocyanine Green Fluorescence Angiography in Complex Abdominal Wall Reconstruction

Lisandro Montorfano, MD; Rene Aleman, MD; Felipe Okida, MD; Fernando Dip, MD, FACS; Samuel Szomstein, MD, FACS, FASMB; Raul Rosenthal, MD, FACS, FASMB; Emanuele Lo Menzo, MD, PhD, FACS, FASMB.

Summary

Complex abdominal wall reconstruction (AWR) carries a significant wound morbidity. Adequate myocutaneous flap perfusion is paramount to decrease such morbidity. However, intraoperative evaluation of abdominal wall perfusion can be challenging, time consuming, and inaccurate. Fluorescence guided imaging of the abdominal wall using the Indocyanine Green (ICG) dye provides an accurate and expeditious real-time assessment of the myocutaneous flap vascular perfusion. Adequate blood flow evaluation with this technique contributes to the reduction of postoperative wound complications and improve patient outcomes following complex abdominal wall reconstruction.^{1,2,3}

The following case study discusses a patient who underwent an open ventral hernia repair, bilateral transversus abdominis release, bilateral myocutaneous flap, insertion of underlay mesh, and excisional debridement of skin after ICG perfusion evaluation.

Patient Background

The patient is a 75-year-old male with a past medical history of chronic alcohol abuse, former smoker, obesity (Body Mass Index of 31.2), prostate cancer, hypertension, hyperlipidemia, diabetes mellitus, coronary artery disease status post coronary artery bypass graft, hypothyroidism, obstructive sleep apnea, chronic kidney disease and depression who presented with a history of a large incisional hernia following a Whipple procedure, which was further complicated by a wound infection which required debridement (**Fig. 1**). Despite several months of wound care, he developed a non-healing wound. Based on the hernia related symptoms and the wound status that was precluding a necessary orthopedic procedure, the patient was referred to our clinic for evaluation. After a comprehensive evaluation and case review at a multicenter hernia conference, he was offered an open ventral hernia repair with bilateral transversus abdominis release, bilateral myocutaneous flap and mesh placement.

Procedure

Preoperative antibiotics, subcutaneous heparin, and sequential compression devices were utilized, as per protocol. An incision was made over the old scar from the xyphoid process to the infraumbilical area. After entering the peritoneal cavity from the upper area, the expected multiple adhesions were taken down. The posterior rectus sheath was separated from the rectus muscle all the way lateral until the perforator vessels were identified and protected. The posterior lamella of the posterior rectus sheath and the transverse abdominis muscle were then divided and the dissection continued in the retroperitoneum. A similar dissection was performed on the opposite side. The posterior rectus sheath was closed. A 20x25mm polypropylene mesh was then placed in the retrorectus space and fixated with absorbable monofilament suture. The anterior rectus sheath was closed under physiologic tension with absorbable monofilament suture. In order to remove the non-healed abdominal wall skin, bilateral cutaneous flaps were created.

Procedure

After a 3.5 mL intravenous injection of Indocyanine Green (ICG), the abdominal wall skin was then evaluated with the IC-Flow™ Imaging System (Diagnostic Green GmbH Aschheim-Dornach Germany) infrared camera (**Fig. 2 and 3**). Based on this evaluation, the non-perfused skin was debrided and excised (approximately 80 cm²). Following the insertion of two closed drains, the skin was closed over. The skin was then closed over two closed suction drains. The patient tolerated the surgery well, and he was discharged without complications on post-operative day three. There were no postoperative complications and no hernia recurrence at his 12 months follow up.

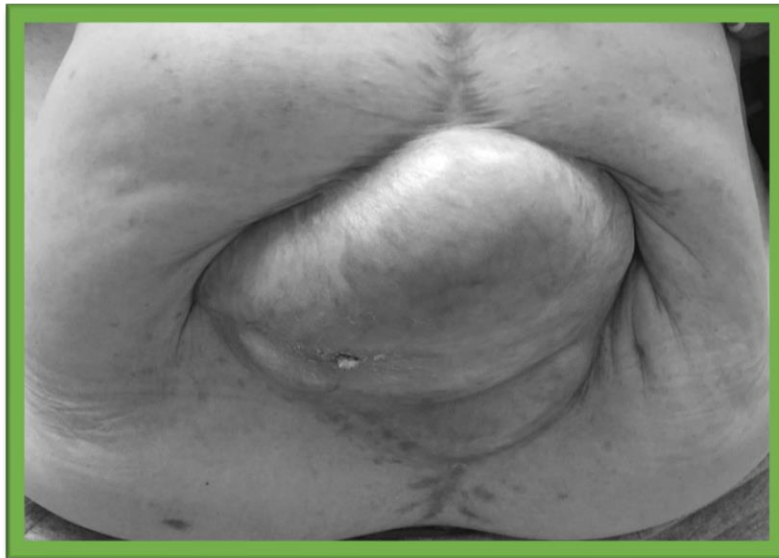

Fig 1. Large incisional hernia with secondary intention healing and skin graft of the middle portion.




Fig 2. Abdominal wall skin evaluated with Indocyanine Green (ICG) demonstrating good vascular perfusion at the wound edges.

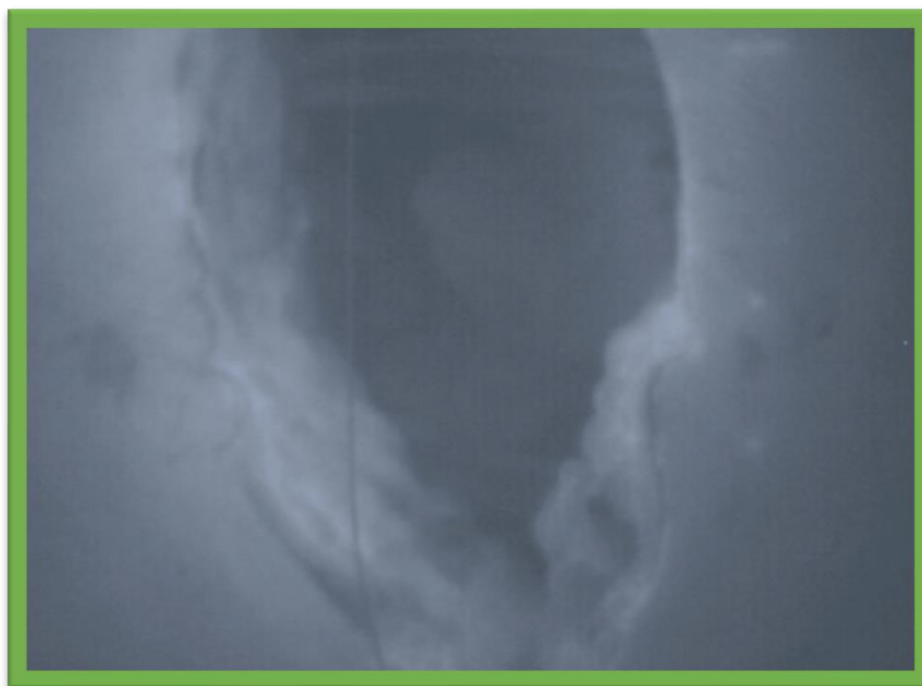


Fig 3. Abdominal wall skin evaluated with Indocyanine Green (ICG)

Conclusion

The use of Indocyanine Green Fluorescence Angiography for real-time assessment of myocutaneous flap perfusion allows for a simple, rapid and safe evaluation of the abdominal wall perfusion. This technique can guide the surgical plan, and help minimize skin flap necrosis and wound complications after abdominal wall reconstruction. Consequently, the technique has the potential to reduce cost and improve patient quality of life.

References

1. Gurtner, G. C., Jones, G. E., Neligan, P. C., Newman, M. I., Phillips, B. T., Sacks, J. M., & Zenn, M. R. Intraoperative laser angiography using the SPY system: review of the literature and recommendations for use. *Ann Surg Innov Res.* 2013;7(1):1. Published 2013 Jan 7. doi:10.1186/1750-1164-7-1
2. Buczek T, Tarnowski W, Kuriata M, Śmietański M. Minimally invasive techniques and indocyanine angiography in anterior abdominal wall reconstruction after multiple laparotomies. *Wideochir Inne Tech Maloinwazyjne.* 2018;13(3):412-416. doi:10.5114/wiitm.2018.75999
3. Patel KM, Bhanot P, Franklin B, Albino F, Nahabedian MY. Use of intraoperative indocyanin-green angiography to minimize wound healing complications in abdominal wall reconstruction. *J Plast Surg Hand Surg.* 2013;47(6):476-480. doi:10.3109/2000656X.2013.787085



Disclosures: LM, RA, FO, have none; SS accepts consulting fees from Medtronic (Fridley, MN), RJR, FD, and ELM accept consulting fees as advisory board members for Diagnostic Green (Farmington Hills, MI). RJR accepts consulting fees from Stryker (Kalamazoo)

Indocyanine Green for Injection, USP is available, in the USA via Diagnostic Green's distributor HUB Pharmaceuticals LLC. Call 1-844-ICG-VIAL (424-8425) or e-mail at info@diagnosticgreen.com for more information. In certain territories across the EMEA, the product is sold under the Verdyne name. For territory specific information, go to www.diagnosticgreen.com.