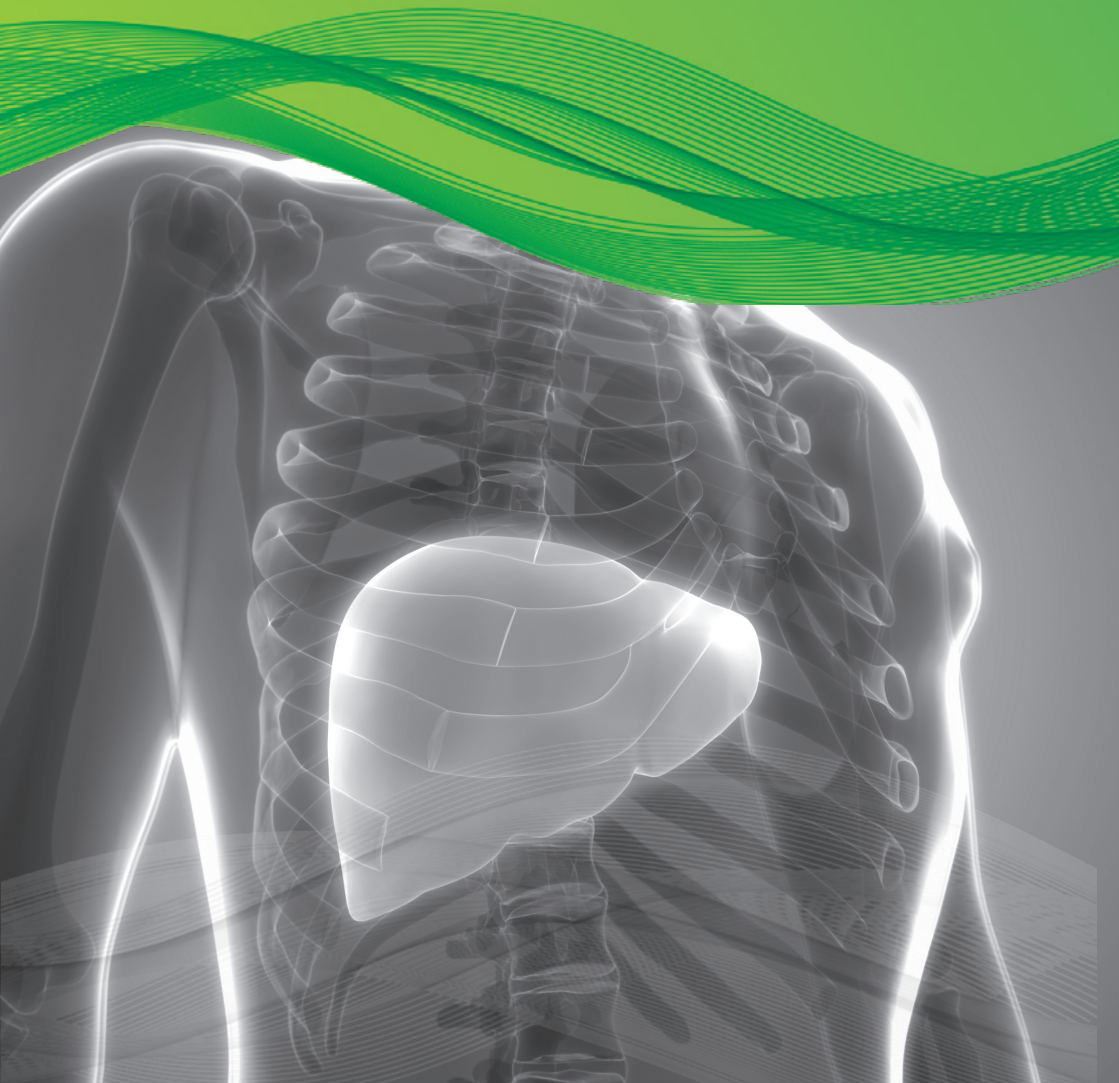


Indocyanine Green for Injection,  
USP (ICG)

# Liver Focus



## Diagnostic Green is the leading provider of trusted high quality fluorescence products, for physicians worldwide.

With primary liver cancer and colorectal liver metastases amongst the most common leading causes of cancer-related deaths worldwide, surgery represents one of the main treatments to obtain the best results in overall and disease free survival.<sup>1</sup> Indocyanine Green for Injection, USP (ICG), in recent years has experienced increased interest in use for its clearance parameters as a dynamic assessment of liver function both in medical and surgical settings.<sup>2</sup> ICG is used routinely to evaluate hepatic function and liver blood flow.<sup>3</sup> It is one of the most common and easy-to-use tests for the perioperative dynamic assessment of liver function in cases of major liver surgery (resective surgery and liver transplantation) and in the intensive care unit.

### USE OF INDOCYANINE GREEN FOR INJECTION, USP, IN LIVER FUNCTION DIAGNOSTICS INCLUDE:

- ⊙ Measurement of excretory function of the liver
- ⊙ Measurement of liver blood flow

While numerous clinical parameters are used to assess a patient's liver function, the ICG test is the gold standard and is the only established test for estimating true global liver function.<sup>4</sup> Assessment of dynamic liver function is crucial in the pre-operative preparation of those who require extensive liver resections, liver transplants and also to monitor liver function in a post-operative setting.

The ICG clearance or the elimination test is the most widely used quantitative liver function test. Following administration of ICG I.V., serial blood samples are collected at 5, 15, 20, 25 & 30 mins. The ICG blood levels fall exponentially for about 20mins, by which time approximately 97% of the ICG is excreted. After processing the samples, the ICG-R15 (at 15 mins) is determined as a percentage.

### QUANTITATIVE MEASUREMENT

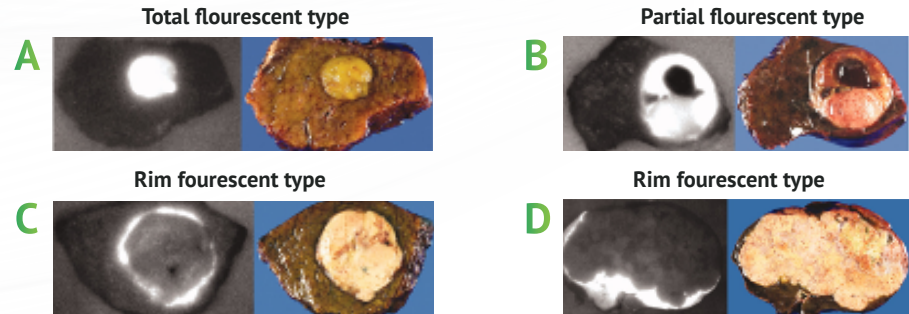
- ⊙ ICG Retention 15mins (ICG-R15) (Normal <10%)
- ⊙ Pulse Dye Densitometry – LiMON device
- ⊙ ICG Plasma Disappearance Rate (ICG-PDR) (Normal > 18%/min)<sup>5</sup>

### ICG CLEARANCE TESTS

- ⊙ Pre and post Liver Resections
- ⊙ Pre and post Liver Transplant Surgery
- ⊙ Acute Liver Failure (ICU setting)

## INDOCYANINE GREEN FOR INJECTION, USP, AND TUMOR VISUALIZATION

For intra-operative visualization of liver tumor, ICG is administered I.V. two weeks prior to surgery.<sup>10</sup>

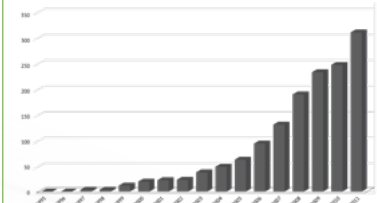


- A** Total fluorescent type – well differentiated hepatocellular carcinoma (HCC), 7mm in diameter
- B** Partial fluorescent type – moderately differentiated HCC with well differentiated components and hemorrhagic necrosis at upper half of the tumor, 36mm in diameter
- C** Rim fluorescent type – poorly differentiated HCC, 30mm in diameter
- D** Rim fluorescent type – metastasis in colon carcinoma, 130mm in diameter

### Italy snapshot of LLR surgeries in practice <sup>11</sup>

- LLR represents 10.3% of all Liver Resections (1677 cases)
- Malignant lesions 72.5% (1085 cases)
  - 56% - Hepatocellular Carcinoma (HCC)
  - 28% - Colorectal Liver Metastases (CRLM)
- Overall mortality 0.2%
- Mean length of stay → five days

### GROWTH IN MINIMALLY INVASIVE LIVER SURGERIES BY YEAR IN ITALY (FROM 50 IN 2005 TO OVER 300 IN 2011)



## SUMMARY OF INDOCYANINE GREEN FOR INJECTION, USP, IN LIVER SETTING

- Liver Function Assessment – Pre & Post Op
- Intra-operative identification of anatomic liver segments
- After reconstruction of hepatic vessels – assessment of liver inflow and outflow of blood
- Visualization of Liver Tumors (HCC & CRLM)\*
- Useful for real-time detection of bile leaks during liver resection
- Supports living donor liver transplantation

\*Note - Tumor Visualization and ICG is currently an investigational use.

## LAPAROSCOPIC LIVER RESECTION (LLR)

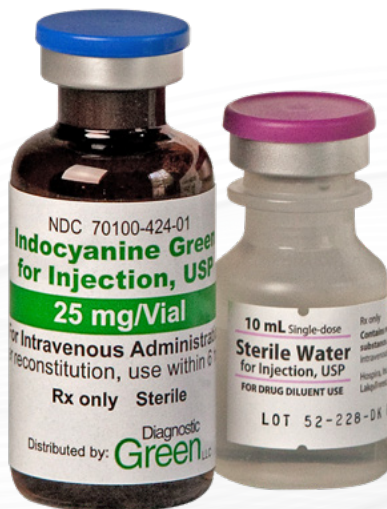Since the first Laparoscopic Liver Resection (LLR) was first performed in 1991, the number of LLR's has increased with the advancements of surgical techniques and technology. LLR for Hepatocellular Carcinoma (HCC) is now considered standard treatment for minor liver resection.<sup>6</sup> Laparoscopic surgery and robotic surgery have solved the issue of large incisional wounds, a major drawback of open liver surgery.<sup>7</sup> While there are significant advantages associated with a laparoscopic technique (less bleeding, shorter length of hospital stay, decreased morbidity and possibly lower mortality), adoption by a surgeon does mean that the ability to touch and palpate the organ is eliminated. By using ICG in these circumstances, increasing the visualization of the anatomy adds to procedure success.

## INDOCYANINE GREEN FOR INJECTION, USP, USE IN LIVER RESECTIONS – FIRST LINE TREATMENT FOR HEPATOCELLULAR CARCINOMA (HCC)

Over the last few decades, imaging technologies in hepatobiliary (HPB) surgery have become indispensable tools for liver surgeons. The ICG fluorescence imaging (FI) technique helps to guide the hepatic surgical procedures and provides the surgeon with real-time visualization of the fluorescent structures of interest that would be invisible under conventional white light. The extrahepatic bile duct anatomy and liver tumors can be emphasised, and hepatic segments highlighted, based on the fluorescence property of ICG and its biliary excretion.

## COLORECTAL LIVER METASTASES AND LIVER TRANSPLANT USE OF ICG

Additionally, a recent retrospective multi-center analysis of 174 patients showed that the use of ICG identifies significantly more and smaller tumors during colorectal liver metastases (CRLM) resection.<sup>8</sup> For liver transplantation, use of ICG has shown to be the best curative treatment of chronic liver diseases/HCC/acute liver failure. Increasing the use of marginal grafts can lead to increased incidence of primary non-function (PNF) after transplantation with few early predictors available for PNF. By undertaking quantitative assessment of intra-operative ICG fluorescence on the graft, a 2020 study has shown that it was feasible to predict graft survival at three months with good sensitivity and specificity.<sup>9</sup>





## INDOCYANINE GREEN FOR INJECTION, USP, USE - BENEFITS TO THE SURGEON

- ⊙ Real time visualization of anatomical structures
- ⊙ Simple method to evaluate hepatic function
- ⊙ Allows for safe use of marginal liver grafts
- ⊙ Easy to use test for dynamic assessment of liver blood flow
- ⊙ Helps identify more and smaller colorectal tumors
- ⊙ Quantitative liver function test

## REFERENCES:

- <sup>1</sup>Torre LA, Bray F, Siegel RL, Ferlay J, Lortet-Tieulent J, Jemal A. Global cancer statistics, 2012. *CA Cancer J Clin*. 2015;65:87–108. [PubMed] [Google Scholar]
- <sup>2</sup>Indocyanine green kinetics to assess liver function: Ready for a clinical dynamic assessment in major liver surgery? Andrea De Gasperi, Ernestina Mazza, and Manlio Prosperi, *World J Hepatol*. 2016 Mar 8; 8(7): 355–367. Published online 2016 Mar 8. doi: 10.4254/wjh.v8.i7.355
- <sup>3</sup>Fluorescence guided surgery in liver tumours: applications and advantages. Rossi Giorgio, Tarasconi Antonio, Baiocchi Gianluca, Luigi de'Angelis Gian, Gaiani Federica, Di Mario Francesco, Catena Fausto, and Dalla Valle Raffaele *Acta Biomed*. 2018; 89(Suppl 9): 135–140. doi: 10.23750/abm.v89i9-S.7974
- <sup>4</sup>Geisel D, Lüdemann L, Hamm B, Denecke T. Imaging-Based Liver Function Tests--Past, Present and Future. *Rofa*. 2015;187(10):863-871. doi:10.1055/s-0035-1553306
- <sup>5</sup>APA Sakka, Samir G. Assessing liver function, *Current Opinion in Critical Care*: April 2007 - Volume 13 - Issue 2 - p 207-214
- <sup>6</sup>Kaneko J, Kokudo T, Inagaki Y, Hasegawa K. Innovative treatment for hepatocellular carcinoma (HCC). *Transl Gastroenterol Hepatol*. 2018;3:78. Published 2018 Oct 22. doi:10.21037/tgh.2018.10.04.
- <sup>7</sup>The history of liver surgery: Achievements over the past 50 years. Norihiro Kokudo, Nobuyuki Takemura, Kyoji Ito, Fuminori Mihara. First published: 26 February 2020 <https://doi.org/10.1002/ags3.12322>
- <sup>8</sup>Handgraaf HJM, Boogerd LSF, Höppener DJ, et al. Long-term follow-up after near-infrared fluorescence-guided resection of colorectal liver metastases: A retrospective multicenter analysis. *Eur J Surg Oncol*. 2017;43(8):1463-1471. doi:10.1016/j.ejso.2017.04.016
- <sup>9</sup>Dousse D, Vibert E, Nicolas Q, et al. Indocyanine green fluorescence imaging to predict graft survival after orthotopic liver transplantation: a pilot study [published online ahead of print, 2020 May 13]. *Liver Transpl*. 2020;10.1002/lt.25796. doi:10.1002/lt.25796
- <sup>10</sup>Shizawa T, Fukushima N, Shibahara J, et al. Real-time identification of liver cancers by using indocyanine green fluorescent imaging. *Cancer*. 2009;115(11):2491-2504. doi:10.1002/cncr.24291
- <sup>11</sup>Aldrighetti L, Belli G, Boni L, et al. Italian experience in minimally invasive liver surgery: a national survey. *Updates Surg*. 2015;67(2):129-140

## INDOCYANINE GREEN FOR INJECTION, USP, PRESCRIBING INFORMATION

### HIGHLIGHTS OF PRESCRIBING INFORMATION

These highlights do not include all the information needed to use Indocyanine Green for Injection USP safely and effectively. See full prescribing information for Indocyanine Green for Injection USP.

For Intravenous Injection - Initial U.S. Approval: 1959

### INDICATIONS AND USAGE

Indocyanine Green for Injection USP, a tricarboyanine dye, is indicated:

- For determining cardiac output, hepatic function and liver blood flow.
- For ophthalmic angiography.

### DOSAGE AND ADMINISTRATION

#### Indicator-Dilution Studies.

Under sterile conditions, the Indocyanine Green for Injection USP powder should be dissolved with the Sterile Water for Injection, USP provided and the solution used within 6 hours after it is prepared. The usual doses of Indocyanine Green for Injection USP for dilution curves are: Adults 5.0 mg, Children - 2.5 mg, and Infants - 1.25 mg.

#### Hepatic Function Studies.

Under sterile conditions, the Indocyanine Green for Injection USP powder should be dissolved with the Sterile Water for Injection, USP provided. The patient should be weighed and the dosage calculated on the basis of 0.5 mg/kg of body weight. Exactly 5 mL of Sterile Water for Injection, USP should be added to the 25 mg vial giving 5 mg of dye per mL of solution.

#### Ophthalmic Angiography Studies.

Dosages up to 40 mg Indocyanine Green for Injection USP dye in 2 mL of Sterile Water for Injection, USP should be administered. A 5 mL bolus of normal saline should immediately follow the injection of the dye.

### DOSAGE FORMS AND STRENGTHS

Indocyanine Green for Injection USP is a sterile, lyophilized green powder containing 25 mg of indocyanine green with no more than 5% sodium iodide.

### CONTRAINDICATIONS

Indocyanine Green for Injection USP contains sodium iodide and should be used with caution in patients who have a history of allergy to iodides because of the risk of anaphylaxis.

### WARNINGS AND PRECAUTIONS

- Deaths due to anaphylaxis have been reported following Indocyanine Green for Injection USP administration during cardiac catheterization.
- Indocyanine Green for Injection USP is unstable in aqueous solution and must be used within 6 hours.
- Radioactive iodine uptake studies should not be performed for at least a week following the use of Indocyanine Green for Injection USP.

### ADVERSE REACTIONS

Most common adverse reactions are anaphylactic or urticarial reactions. These have been reported in patients with and without a history of allergy to iodides.

To report SUSPECTED ADVERSE REACTIONS, contact Diagnostic Green LLC at 1-844-424-3784 (1-844-ICG-DRUG) or e-mail: [drugsafety@diagnosticgreen.com](mailto:drugsafety@diagnosticgreen.com); or FDA at 1-800-FDA-1088 or [www.fda.gov/medwatch](http://www.fda.gov/medwatch).

### DRUG INTERACTIONS

Products containing sodium bisulfite reduce the absorption peak of Indocyanine Green for Injection USP in blood.

For full prescribing information go to [www.diagnosticgreen.com](http://www.diagnosticgreen.com)

Diagnostic  
Green

© 2020 Diagnostic Green  
[info@diagnosticgreen.com](mailto:info@diagnosticgreen.com)  
[www.diagnosticgreen.com](http://www.diagnosticgreen.com)

Diagnostic Green GmbH  
Otto-Hahn-Straße 20  
85609 Aschheim-Dornach  
Germany

Diagnostic Green LLC  
38955 Hills Tech Drive  
Farmington Hills  
MI 48331, United States